

ΠΕΡΙΠΤΩΣΗ CASE REPORT

Παχυδερμοδακτυλία: η συμμετρική διόγκωση δέρματος στις εγγύς φαλαγγικές αρθρώσεις μπορεί να διαγνωσθεί εσφαλμένα ως αρθρίτιδα

Ευαγγελία Γεωργίου, MD¹, Μαριάννα Βλάχου, MD, DM², Λάζαρος Σακκάς, MD, DM, PhD (London), FRCP (London)¹

¹Ρευματολογική Κλινική και ²Εργαστήριο Ακτινολογίας, Πανεπιστημιακό Γενικό Νοσοκομείο Λάρισας και Ιατρική Σχολή, Πανεπιστήμιο Θεσσαλίας, Λάρισα, Ελλάδα

ΠΕΡΙΛΗΨΗ

Η παχυδερμοδακτυλία είναι μια καλοήθης κατάσταση αγνώστου αιτιολογίας, που εκδηλώνεται με πάχυνση του δέρματος γύρω από τις εγγύς φαλαγγικές αρθρώσεις (PIP). Τις περισσότερες φορές, η διόγκωση είναι συμμετρική και μπορεί εύκολα να διαγνωσθεί εσφαλμένα ως αρθρίτιδα, ιδιαίτερα νεανική ιδιοπαθής αρθρίτιδα ή η ρευματοειδής αρθρίτιδα.

Υπεύθυνος αλληλογραφίας:

Καθηγητής Λάζαρος Ι. Σακκάς
Καθηγητής Παθολογίας-Ρευματολογίας,
Διευθυντής Ρευματολογικής Κλινικής,
Ρευματολογική Κλινική, Ιατρικό Τμήμα,
Σχολή Επιστημών Υγείας,
Πανεπιστήμιο Θεσσαλίας
Βιόπολις 41110, Λάρισα
Τηλ.: 2413502813, Fax: 2413501016,
E-mail: lsakkas@med.uth.gr

Corresponding author:

Professor Lazaros I. Sakkas
Department of Rheumatology
Faculty of Medicine,
School of Health Sciences,
University of Thessaly and University
General Hospital of Larissa
Biopolis 41110, Larissa
Tel: +302413502813, Fax: +302413501016,
E-mail: lsakkas@med.uth.gr

Mediterr J Rheumatol 2016; 27(1): 50-53

Λέξεις-Κλειδιά: Παχυδερμοδακτυλία, νεανική ιδιοπαθής αρθρίτιδα, ρευματοειδής αρθρίτιδα

Pachydermodactyly-symmetric soft tissue swelling around proximal interphalangeal joints may be misdiagnosed for arthritis

Evangelia Georgiou, MD¹, Marianna Vlychou, MD, DM², Lazaros I. Sakkas, MD, DM, PhD (London), FRCP (London)¹

Department of ¹Rheumatology and ²Radiology, Faculty of Medicine, School of Health Sciences, University of Thessaly, Larissa 41110, Greece

ABSTRACT

Pachydermodactyly is a benign condition of unknown aetiology that presents with skin thickening around the proximal interphalangeal (PIP) joints. Most of the time the swelling is symmetrical and can easily misdiagnosed for arthritis, particularly juvenile idiopathic arthritis or rheumatoid arthritis.

Mediterr J Rheumatol 2016; 27(1): 50-53

Keywords: pachydermodactyly, juvenile idiopathic arthritis, rheumatoid arthritis

Case report

A 15 year-old pleasant boy with no medical history, presented with swelling of the proximal interphalangeal joints of both hands for the last 2 years. He was a high school student and spent a lot of time playing basketball. He reported no pain, morning stiffness, fever, itching, rash, or any other symptom. Family history revealed a father with Hodgkin's lymphoma. He had symmetric swelling of the second through forth proximal interphalangeal joints bilaterally, without tenderness and had normal joint range of movements. There was no uveitis. Full blood count and basic biochemistry tests were normal. Erythrocyte and C-reactive protein were normal. Rheumatoid factor, anti-CCP antibodies, and antinuclear antibodies were all negative. The patient started on methotrexate without any benefit. Etanercept was also totally ineffective in reducing the swelling. A review of his case revealed skin thickening on the medial, lateral and dorsal aspect of PIP joints (**Figure 1A**). Skin biopsy showed hyperplasia of the epidermis increased collagen in the dermis, and superficial mild perivascular inflammation. Ultrasound showed skin thickening with no power Doppler signal and no joint abnormality. MRI of hands showed edema of soft tissue around the PIP joints, but no joint inflammation or periosteal abnormality (**Figure 1B,C**). Based on these findings, pachydermodactyly was diagnosed and medications were stopped. A year later the boy is well with no progression of PIP swelling.

COMMENTS

Pachydermodactyly is a rare benign condition that affects young individuals and rarely adults. Increased mechanical irritation, such as coming from sports, or musical instruments, is thought to be an attributing factor. It presents with painless soft tissue swelling over the medial, lateral and dorsal aspects of PIP joints of fingers, mostly symmetrical. It can rarely affect a single joint, distal interphalangeal joints, thumbs, and toes.^{1,2} Histology shows increased collagen deposition in dermis, hyperkeratosis (hyperplasia of stratum corneum) and acanthosis

(hyperplasia of stratum spinosum). Mononuclear cell infiltration has rarely been reported. Practitioners should be familiar with pachydermodactyly because they may misdiagnose it for juvenile arthritis and subject individuals to unnecessary and potentially harmful drug treatments. The absence of pain and tenderness, and the normal range of joint movements point to the correct diagnosis. Careful physical examination reveals that the joint swelling is due to periarticular soft tissue thickening and not to joint inflammation. Ultrasound confirms the absence of joint inflammation of PIP joints. MRI shows no evidence of capsule, ligament, tendon, or periosteum involvement.³ Differential diagnosis, apart from arthritis, includes knuckle pads (Garrod's pads) (skin thickening over the dorsal aspect of hand joints), and pachydermoperiostosis. The latter is a painful condition characterized by pachydermopathy, digital clubbing, and periostosis.

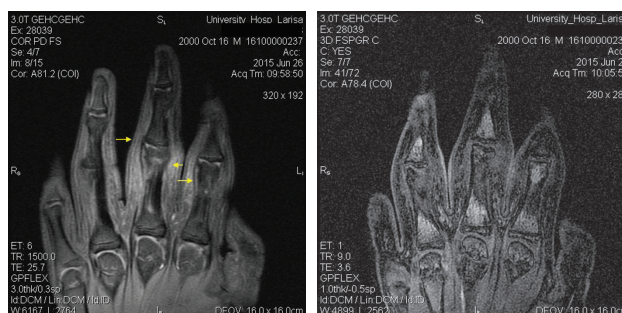
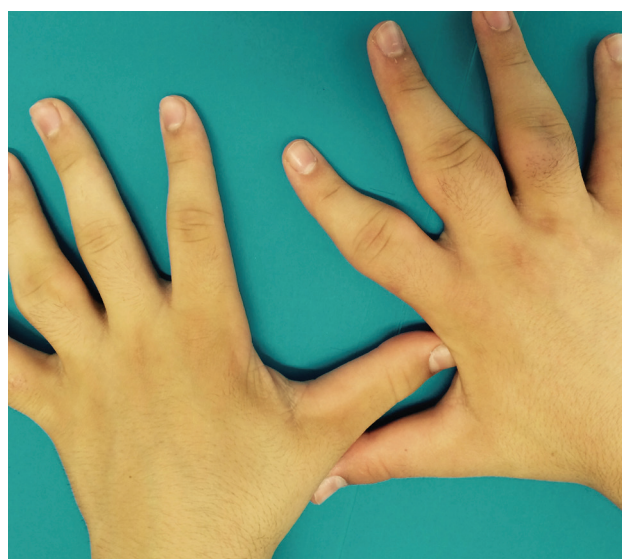

Figure 1 (A) Patient's hands with fusiform swelling of proximal interphalangeal joints. **(B)** Coronal proton-density weighted image with fat saturation shows normal proximal interphalangeal joints, with no evidence of inflammation. There is mild edema of the periarticular subcutaneous tissue (arrows) with minor signal increase. **(C)** Coronal 3D-SPGR with fat saturation after contrast administration shows normal small joints, without evidence of contrast enhancement in synovium or tendons.

CONFLICT OF INTEREST

None declared

REFERENCES

1. El-hallak M, Lovell D. Pachydermodactyly mimicking juvenile idiopathic arthritis. *Arthritis Rheum* 2013;65:2736
2. Dallos T, Oppl B, Kovacs L, Zwerina J. Pachydermodactyly: A review. *Curr Rheumatol Rep* 2014;16:442
3. Anandacoomarasamy A, Bak HS, Peduto A, Manolios N. Magnetic resonance imaging in pachydermodactyly. *J Rheumatol* 2005;32:2239-41